# Mastitis and the use of ultrasound in practice

Ultrasonography is a non-invasive technique that can be used for examining the bovine udder and teats. For high milk production in cows, it is important to keep a well-structured udder and teats, as they are more resistant to the long-term impact of milking equipment.

Different types of mastitis leads to loss and adverse changes in the quality of milk. Increased costs for treatment and early culling of the animals make up the negative economic effect.

**by O. Escobedo and L. Gil, Veterinary University of Zaragoza, Spain, and Y. Trillo, DVM, BCF technology. www.bcftechnology.comby**

Udder ultrasound is a complementary tool to help diagnose the following:

- In the gland parenchyma: mastitis; pathological changes in the udder, such as inflammation; without clinical signs of mastitis (haematoma, neoplasia, abscess, etc) and foreign bodies.
- In the teat: stenosis, inflammation, mucosal lesions, tissue proliferation, milk stones, congenital changes and fused teats.
- In the teat canal and Fürstemberg's rosette: inflammation and mucosal lesions.
- In the teat cistern: inflammation, milk stones, tissue proliferation and congenital malformations.

Ultrasonography is increasingly used for examination and measurement of different anatomical structures (length and diameter of the teat canal, cistern, and the thickness of the teat wall). Many authors have found a relation between mastitis in cows, the characteristics of the teat, the stage of lactation and the visualisation of the teat canal.

The main indication of this technique is to appreciate milk flow disorders. Inadequate milking technique or teat handling are the most common causes of altered milk flow. These can produce total stenosis or partial

*Continued on page 12*

| | Cow 1 | Cow 2 | Cow 3 | Cow 4 |
|---|---|---|---|---|
| |  |  |  |  |
| Diagnosis | Healthy (control) | Acute mastitis | Colibacilar acute mastitis | Chronic mastitis |
| Symptoms | – | Milk clots | Pain at palpation (1 week) and decreased milk production | High somatic cells and decreased milk production |
| Delivery date | 2 months | 7 days | 5 months | 6 months |
| Milk production (litres/day) | 34 | 42 | 4 | 31 |
| Age (years) | 6 | 4 | 4 | 5 |
| Affected quarter | Normal | Frontal right | All | All |
| Average quarters Temp. (°C) | 38.1 | 37.8 | 38.0 | 37.7 |
| Treatment | – | 2 days enrofloxacin and AINE (parenteral) | Enrofloxacin and AINE (parenteral) | AINE during clinical mastitis periods |
| Mammary gland 1 | 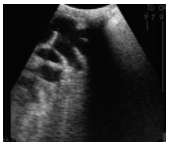 |  | 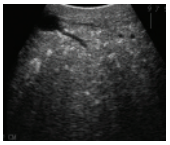 |  |
| Mammary gland 2 |  |  |  | 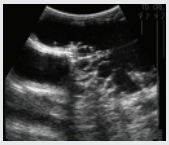 |
| Teat | 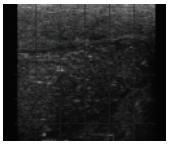 |  | 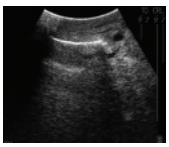 | 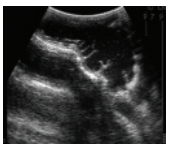 |

*All images were obtained from an Easi-Scan Curve (3 to 7MHz probe) in the milking parlour.

**Table 1. Right, results of the clinical examination and ultrasound images of three udders with mastitis versus a normal healthy udder.**

*Continued from page 11*
stenosis of the proximal, medial and/or distal part of the teat.

However, ultrasonography of the teat allows for the localisation and appreciation of the extent of pathological changes and therefore is an important additional diagnostic tool.

The correct use of B-mode ultrasonography equipment allows for the differentiation of morphological structures. When scanning the udder, as with any other structure, ultrasound waves do not pass through the air easily, and therefore it is essential to apply ultrasound gel to the teat to eliminate any air and achieve a good quality image (see photograph right).

**Scanning the udder using an Easi-Scan.**

## Comparison of ultrasound images

Table 1 on the previous page compares teat ultrasound images obtained from cows with different types of mastitis. The objective was to demonstrate the pathological changes of the teat and mammary gland from acute to chronic mastitis stages by comparison with a normal udder.

In cow 1, the udder parenchyma has a homogenous echogenicity with some anechoic visible veins. The milk of the cistern gland is anechoic with some small particles. The ducts are clearly visible as they enter the cistern gland.

In cows 2 and 3 the udder parenchyma has several small hyperechoic regions due to inflammation. The milk within the cistern and teat has increased echogenicity, with echogenic spots due to the increased cellular content. The teat shows thick and irregular tissue due to inflammation and oedema.

In cow 4 there is poor visualisation, loss of the parenchyma and increased echogenicity due to fibrosis. Tissues have been destroyed, especially at the junction of the wall with the cistern (fibrotic tissue after inflammation – cicatrisation mechanism). Milk in the cistern appears more contaminated (echogenic spots) than in the acute cases. In cow 2, the cistern milk has decreased overall due to oedema of the wall compressing the cistern, while in chronic cases there is a distension of the gland cistern due to a breakdown of tissues around the cistern.

The teat images from cows 2, 3 and 4 demonstrate increasing severity of pathology within the echogenic pattern of the glandular structures, fibrosis and reducing demarcation between gland and teat.

These observations were specifically described for each case. However, abnormalities of the udder may vary with the causative organism.

## Conclusion

In conclusion, the ultrasound patterns observed across these cases aid in the differentiation between normal and pathological cases and help to assess the degree of severity of disease.

Ultrasound provided additional information of the udder status to help determine antibiotic treatment (selective use of antibiotics), treatment time of the case and future prognostics. ■

References are available from the author on request